

Ilyicheva E.A. <sup>1,2</sup>, Zharkaya A.V. <sup>1,2</sup>, Bulgatov D.A. <sup>2</sup>, Makhutov V.N. <sup>2</sup>, Borichevskiy V.I. <sup>2</sup>, Karasev V.P. <sup>2</sup>, Aldaranov G.Yu. <sup>2</sup>, Ovakimyan G.A. <sup>2</sup>

## EXPERIENCE OF SURGICAL TREATMENT OF THYROID AND PARATHYROID DISEASES

<sup>1</sup> Irkutsk Scientific Centre of Surgery and Traumatology  
(ul. Bortsov Revolyutsii 1, Irkutsk 664003, Russian Federation)

<sup>2</sup> Irkutsk Regional Clinical Hospital  
(Yubileyniy 100, Irkutsk 664079, Russian Federation)

<sup>3</sup> Irkutsk State Medical University  
(ul. Krasnogo Vosstaniya 1, Irkutsk 664003, Russian Federation)

*Background.* In our country some aspects of thyroid and parathyroid surgery are still discussed.

*Aim.* To present our experience in surgical treatment of benign diseases of the thyroid and parathyroid glands.

*Materials and methods.* A retrospective analysis of the results of surgical treatment of 1511 patients with thyroid and parathyroid disease was performed.

*Results.* Thyroidectomy was performed in 73.6 % of cases with thyroid diseases. The frequency of postoperative complications: laryngeal paresis – 1.37 %, hypoparathyroidism – 0.84 %, hemorrhagic complications – 1.2 %. Selective parathyroidectomy was performed in 99 % of cases with primary hyperparathyroidism. Persistent hypoparathyroidism and laryngeal paresis have not been identified. Total parathyroidectomy with central neck dissection, upper mediastinum and upper horn of the thymus gland was performed in 66.3 % of cases with secondary hyperparathyroidism. Persistent laryngeal paresis was established in 3.3 % of cases, hemorrhagic complications – in 3.3 %.

*Conclusions.* Constant analysis of our own results gives us reasons for our own attitude to the controversial issues of thyroid and parathyroid surgery. Presently, we prefer thyroidectomy in the treatment of diffuse toxic goiter and multinodular goiter, hemithyroidectomy – for the single-node goiter. In the surgical treatment of primary and uremic hyperparathyroidism, we consider mandatory the use of intraoperative monitoring of intact parathyroid hormone. When performing total parathyroidectomy, we perform the autotransplantation of the fragment of the parathyroid gland.

**Key words:** thyroidectomy, parathyroidectomy

## ОПЫТ ХИРУРГИЧЕСКОГО ЛЕЧЕНИЯ ДОБРОКАЧЕСТВЕННЫХ ЗАБОЛЕВАНИЙ ЩИТОВИДНОЙ ЖЕЛЕЗЫ И ОКОЛОЩИТОВИДНЫХ ЖЕЛЕЗ

Ильичева Е.А. <sup>1,2</sup>, Жаркая А.В. <sup>1,2</sup>, Булгатов Д.А. <sup>3</sup>, Махутов В.Н. <sup>2</sup>, Боричевский В.И. <sup>2</sup>, Карасев В.П. <sup>2</sup>, Алдаранов Г.Ю. <sup>2</sup>, Овакимян Г.А. <sup>2</sup>

<sup>1</sup> ФГБНУ «Иркутский научный центр хирургии и травматологии»  
(664003, г. Иркутск, ул. Борцов Революции, 1, Россия)

<sup>2</sup> ГБУЗ «Иркутская орден «Знак почёта» областная клиническая больница»  
(664079, г. Иркутск, Юбилейный, 100, Россия)

<sup>3</sup> ФГБОУ ВО «Иркутский государственный медицинский университет» Минздрава России  
(664003, г. Иркутск, ул. Красного Восстания, 1, Россия)

*Обоснование.* На сегодняшний день некоторые хирургические аспекты лечения доброкачественных заболеваний щитовидной и околощитовидных желёз остаются широко обсуждаемыми. Цель исследования: представить опыт коллектива в хирургическом лечении доброкачественных заболеваний щитовидной железы и околощитовидных желёз.

*Методы.* Проведён ретроспективный анализ результатов хирургического лечения 1511 пациента, оперированного по поводу доброкачественных заболеваний щитовидной железы и околощитовидных желёз за период с 2005 г. по апрель 2017 г. в торакальном хирургическом отделении ГБУЗ ИОКБ.

*Результаты.* При заболеваниях щитовидной железы в 73,6 % случаев выполнялась тиреоидэктомия. Частота послеоперационных осложнений: парез гортани – 1,37 % случаев, гипопаратиреоз – 0,84 %, геморрагические осложнения – 1,2 %. При первичном гиперпаратиреозе в 99 % случаев выполнена селективная паратиреоидэктомия. Стойкого гипопаратиреоза и пареза гортани не выявлено. При вторичном гиперпаратиреозе в 66,3 % случаев выполнена тотальная паратиреоидэктомия с диссекцией центральной клетчатки шеи, верхнего средостения и верхних рогов вилочковой железы. Стойкий парез гортани был установлен в 3,3 % случаев, геморрагические осложнения – в 3,3 %.

*Заключение.* Постоянный этапный анализ собственных данных позволяет аргументировать отношение авторов к спорным вопросам хирургии доброкачественных заболеваний щитовидной и околощитовидных желёз. Аргументация связана с низким риском персистенции и рецидива заболеваний, приемлемой частотой послеоперационных осложнений и отсутствием летальности.

**Ключевые слова:** тиреоидэктомия, паратиреоидэктомия

To date, the pathology of the thyroid and parathyroid glands occupy the second and third place in terms of prevalence among diseases of the endocrine system after diabetes mellitus [4]. Surgery of diseases of the thyroid and parathyroid glands is the continuously developing direction of general surgery with changing views on indica-

tions for surgical treatment and tactical aspects. The most topical issues are the questions of differential diagnosis of primary and secondary hyperparathyroidism, the use of intraoperative monitoring in the surgical treatment of primary and uremic hyperparathyroidism, and the choice of the scope of surgical intervention in secondary

hyperparathyroidism. Discussion remains in the choice of the volume of surgical intervention for diffuse toxic and multi-node goiter.

In 2004, the authors called oncological alertness as the main cause of operative activity in cases of nodular goiter. Hypothyroidism was regarded as a complication of surgical treatment, and surgeons kept to organ-preserving resections of the thyroid gland [1]. The Clinical recommendations of the Russian Association of Endocrinologists for the diagnosis and treatment of nodular goiter (2004) identified two groups of indications for surgical treatment: a nodal (multinodular) goiter with signs of compression of surrounding organs and/or cosmetic defect and nodal (multinodular) goiter in the presence of decompensated functional autonomy thyroid gland (toxic goiter) or at a high risk of its decompensation [5].

For 2008, the most common volume of surgical intervention for Graves disease in Russia was subtotal resection of the thyroid gland. This volume of surgery was considered necessary to maintain the patient's euthyroid status in the postoperative period [12]. Other domestic authors showed that thyroidectomy can significantly reduce the risk of relapse of thyrotoxicosis in comparison with subtotal resections of the thyroid gland, in the absence of an increase in the incidence of complications and deterioration in the quality of life [11]. In the Clinical Recommendations of the Russian Endocrinology Association in 2007, the goal of surgical treatment was to remove the greater part of the thyroid gland ensuring the development of postoperative hypothyroidism (which is not currently considered a complication of surgical treatment of Graves disease but is considered its goal), excluding any possibility of relapse of thyrotoxicosis [3].

This discussion is still ongoing. The authors indicate (2015) that the volume and method of surgical intervention for diffuse toxic goiter should be selected individually, taking into account the severity of the disease, the presence or absence of endocrine ophthalmopathy, the titer of antibodies to thyroid-stimulating hormone receptors, the age and duration of antithyroid therapy [10]. In the Clinical recommendations of the Russian Endocrinology Association in 2014, the total thyroidectomy is indicated as operative treatment of choice for diffuse toxic goiter [10].

To this day surgical tactics regarding secondary (uremic) hyperparathyroidism remains the subject of discussions. There is no generally accepted recommended volume of surgical treatment [2]. The main problem of choosing surgical tactics in the treatment of patients with chronic kidney disease at the dialysis stage, suffering from severe secondary hypoparathyroidism, is the lack of consensus on the purpose of the operation – achieving target levels of parathyroid hormone or hypoparathyroidism and the absence of a risk of persistence and relapse of the disease.

As we have accumulated experience in the treatment of benign thyroid and parathyroid pathologies, we find this report to be very important.

#### AIM OF THE STUDY

To present the team's experience in the surgical treatment of benign diseases of the thyroid gland and parathyroid glands.

#### MATERIALS AND METHODS

We have conducted a retrospective analysis of the results of surgical treatment of patients operated for benign thyroid and parathyroid gland diseases in the thoracic surgical department of the Irkutsk Regional Clinical Hospital for the period from 2005 to April 2017. The criterion for inclusion in the study was a surgical intervention for benign diseases of the thyroid gland and parathyroid glands. The criterion for exclusion from the study was the lack of consent to the processing of personal data. The inclusion criteria totaled 1511 cases, all observations included in the study.

Table 1 presents the distribution of surgeries by year.

**Table 1**  
*Dynamics of surgical activity for diseases of thyroid and parathyroid glands*

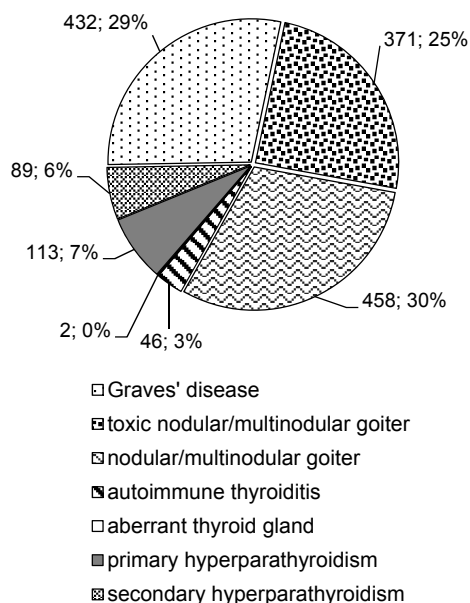
Year	Number of surgeries for diseases of thyroid gland	Number of surgeries for primary hyperparathyroidism	Number of surgeries for secondary hyperparathyroidism
2005	0	0	1
2006	119	0	1
2007	144	5	1
2008	31	0	0
2009	121	9	1
2010	110	3	5
2011	108	1	5
2012	91	5	5
2013	111	10	6
2014	90	15	11
2015	162	23	21
2016	170	32	22
before April 2017	52	10	10
<b>Total:</b>	<b>1309</b>	<b>113</b>	<b>89</b>

Mean age – 51 (40; 59) y.o., most patients were women (88.7 %).

In the structure of the underlying disease, multinodular or nodal goiter and diffuse toxic goiter prevailed (Figure 1). A high percentage of operations for diffuse toxic goiter, in our opinion, is associated with the continued low availability of radioiodine therapy in our country, in particular in the Irkutsk region.

Indications for surgical treatment for thyroid diseases were: nodal or multinodular goiter with signs of compression of the neck (trachea, esophagus), nodular or multinodular goiter with decompensation of functional autonomy, relapse of thyrotoxicosis in diffuse toxic goiter, intolerance to thyrostatics, diffuse toxic goiter with compression of the organs of the neck.

Indications for surgical treatment for primary hyperparathyroidism were as follows: manifest form of primary hyperparathyroidism, daily excretion of calcium with urine more than 10 mmol/L per day, decrease in glomerular filtration rate of kidneys less than 60 ml/min/1.73 m<sup>2</sup>, progressive decrease in bone mineral density on the background of conservative therapy, age younger than 50 years.



**Fig. 1.** Disease structure in patients operated for benign thyroid and parathyroid gland pathologies.

Indications for surgical treatment for secondary hyperparathyroidism were: increased PTH levels of more than 800 pg/mL in combination with hyperphosphataemia resistant to conservative therapy, the presence of extraskeletal calcification, hypercalcemia, or progressive skeletal lesion.

The statistical processing of the results was performed with the use of Statistica 10 for Windows software package (license No. AXAR402G263414FA-V). The normal distribution of the feature was analyzed using the Kolmogorov-Smirnov test. The quantitative data were presented as a median with interquartile range (Me (Q25; Q75)).

When performing surgeries on the thyroid and parathyroid glands, we use microsurgical technique (with amplification), with visualization of recurrent laryngeal nerves and parathyroid glands. The structure of the performed surgical interventions is presented in Table 2.

**Surgeries performed for diseases of thyroid and parathyroid glands**

**Table 2**

Volume of the surgery	Number	
	abs.	%
Subtotal resection of the thyroid gland	8	0,53
Maximally subtotal resection of the thyroid gland	137	9,07
Thyroidectomy (including extirpation of the thyroid stump)	964	63,80
Hemithyroidectomy	198	13,10
Parathyroidecomy	112	7,41
Total parathyroidecomy	13	0,86
Subtotal parathyroidecomy	17	1,13
Total parathyroidectomy with dissection of the central cellular tissue of the neck and mediastinum	59	3,90
Removal of the aberrant ectopic lobe of the thyroid gland	2	0,13
Removal of ectopic parathyroid adenoma	1	0,07
<b>Total:</b>	<b>1511</b>	<b>100</b>

**RESULTS AND DISCUSSION**

When analyzing the structure of surgeries for the pathology of the thyroid gland (Table 2), it was found that in the vast majority of cases, thyroidectomy was performed (73.6%), which is related to predomination of multinodular goiter and diffuse toxic goiter in the structure of diseases. From our point of view, the performance of thyroidectomy is pathogenetically justified method of treating this pathology. With a unilateral pathological process, the minimum volume of surgery performed in our clinic is hemithyroidectomy with removal of the thyroid isthmus.

There was no postoperative lethality. Postoperative resistant hypoparathyroidism was established in 11 cases (0.84 %), which does not exceed the data known in the literature [15]. Hemorrhagic complications in the early postoperative period developed in 16 cases (1.2 %), laryngeal transit paresis – in 182 cases (13.9 %), persistent laryngeal paresis – in 18 cases (1.37 %), which also fits within known limits of frequency of these complications [13]. In 2 cases (0.15 %) tracheal perforation was established: in 1 observation, the lesion was established intraoperatively with a thyroid volume exceeding 300 cm<sup>3</sup>, in 1 case the perforation was established in the early postoperative period and was associated with the use of electrocoagulation. In both cases, after the suturing of the defect of the tracheal wall, recovery occurred.

Pathomorphological study of surgical material in the nodal and multinodular goiter detected 58 cases of highly differentiated thyroid cancer (3.84 %).

When analyzing the structure of surgeries for primary hyperparathyroidism, we have found that in the vast majority of cases parathyroidectomy (99.1%) was performed with removal of one or several pathologically altered parathyroids, and there was 1 (0.9 %) case of subtotal parathyroidectomy with multiple parathyroid lesions. Repeated surgeries in the early postoperative period in connection with the persistence of the disease were performed in 2 cases (1.8 %), in the long-term period – in 1 patient (0.9 %). 59 surgical interventions (52.2 %) were accompanied by intraoperative monitoring of the level of intact parathyroid blood hormone. The use of an intraoperative test of the degree of reduction in the level of intact parathyroid hormone after parathyroidectomy (according to the Miami criterion), in our opinion, allows to reduce the amount of persistence of the disease, but requires the specification of the surgeon's tactics in case of negative sample result [8].

Multiple lesion of the parathyroid by the results of our study made 11 %, which fits into the known data.

Surgical activity in relation to primary hyperparathyroidism has been increasing during the last 3–4 years (Table 1), which, in our opinion, is a consequence of improving the quality of diagnosis of this disease. There were no postoperative lethality, wound septic complications or bleedings. The laryngeal paresis developed in 10 cases (8.9 %) and was transient in all cases.

In secondary (uremic) hyperparathyroidism, total parathyroidectomy with a dissection of the central cellular tissue of the neck, the superior mediastinum and the upper horns of the thymus gland was performed in 59 cases (66.3 %). The choice of this volume of surgical

treatment was based on the analysis of our own data [6, 7]. Absence of synchronicity of pathological changes in the parathyroid glands at uremic hyperparathyroidism and their unavoidable progression due to chronic kidney disease leads to persistence and relapse of the disease, which is an unfavorable outcome, increasing the risk of developing cardiovascular complications. Total parathyroidectomy with the removal of the parathyroid glands of all possible localizations accessible from the cervical approach (including the thyroid gland with established ectopia, the central cellular tissue of the neck and upper mediastinum, the upper horn of the thymus gland) is the only surgical intervention that allows removing parathyroid glands in whole, including parts not detectable with intraoperative revision. This volume of surgery does not increase the risk of postoperative complications in comparison with subtotal parathyroidectomy and standard total parathyroidectomy.

Postoperative paresis of the larynx developed in 5 cases (5.6 %), in three of them (3.3 %) it was of transient nature. In three cases (3.3 %), the larynx paresis was observed after repeated surgery on the neck, including one case (1.1 %) after necessary resection of the recurrent laryngeal nerve against the background of advanced parathyroidism.

Hemorrhagic complications were revealed in three cases (3.3 %). In two cases, complications were presented by subcutaneous hematoma and bleeding from the drainage canal, which did not require recervitotomy. These complications can be associated with the four-hour programmed hemodialysis with the use of heparin in the early postoperative period. In 1 case (1.1 %), a tense mediastinal hematoma developed after sternotomy when an adenoma grown into the aortopulmonary window was removed, the complication was eliminated using a video-assisted mini-thoracotomy. The frequency of hemorrhagic complications in our study did not exceed the values reported by other authors - from 2 % to 4.3 % (bleeding, neck necrosis, requiring surgical drainage) [14, 16].

Simultaneous operations were performed in 47 cases (3.1 %): parathyroidectomy with concomitant hyperparathyroidism in thyroid pathology – 21 cases (44.7 %); hemithyroidectomy and thyroidectomy with concomitant thyroid gland pathology during surgery for secondary hyperparathyroidism – 8 cases (17 %); resection of the internal carotid artery in pathological tortuosity – 9 cases (19.2 %); lobectomy for lung tuberculosis – 1 case (2.1 %); cholecystectomy for chronic calculous cholecystitis – 1 case (2.1 %); inguinal hernia repair – 1 case (2.1 %); stabilization of vertebral bodies with metal cages – 1 case (2.1 %); removal of peritoneal catheter – 1 case (2.1 %); removal of the trachea diverticulum – 1 case (2.1 %); removal of the esophageal diverticulum – 1 case (2.1 %); herniolaparotomy with plastic mesh prosthesis – 1 case (2.1 %); herniolaparotomy with local flaps grafting – 1 case (2.1 %).

### CONCLUSION

In the surgical treatment of benign diseases of the thyroid and parathyroid glands there remains a considerable number of controversial points. At the same time,

a detailed analysis of immediate and remote results of surgeries performed in our clinic gives us reason for our own attitude to some contentious issues. Currently, we prefer thyroidectomy in the treatment of diffuse toxic goiter and multinodal goiter, and hemithyroidectomy for a single-node goiter. In the surgical treatment of primary and uremic hyperparathyroidism, we consider it mandatory to use intraoperative monitoring of intact parathyroid hormone. When performing total parathyroidectomy, we perform autotransplantation of the parathyroid gland fragment.

The authors declare that there is no conflict of interest regarding the publication of this article.

### REFERENCES

1. Аристархов В.Г., Фурсов А.А., Пузин Д.А. О причинах послеоперационного гипотиреоза у больных узловым коллоидным зобом // Российский медико-биологический вестник им. академика И.П. Павлова. – 2004. – № 3-4. – С. 101–104.  
Aristarkhov VG, Fursov AA, Puzin DA. (2004). On the causes of postoperative hypothyroidism in patients with nodular colloid goiter [O prichinakh posleoperatsionnogo gipotireoza u bol'nykh uzlovym kolloidnym zobom]. *Rossiyskiy mediko-biologicheskiy vestnik im. akademika I.P. Pavlova*, 3 (4), 101-104.
2. Ассоциация нефрологов, Научное общество нефрологов России. Минеральные и костные нарушения при хронической болезни почек (Национальные рекомендации) [Электронный ресурс]. – 2015. – Режим доступа: <http://www.nephro.ru/content/files/recomendations/ckdmbdNationalGuidelines.pdf> (дата обращения 31.07.2017).  
Association of Nephrology, Scientific Society of Nephrology of Russia. (2015). Mineral and bone disorders in chronic kidney disease (National recommendations) [*Mineral'nye i kostnye narusheniya pri khronicheskoy bolezni pochek (Natsional'nye rekomendatsii)*]. Available at: <http://www.nephro.ru/content/files/recomendations/ckdmbdNationalGuidelines.pdf> (date of access 31.07.2017).
3. Дедов И.И., Мельниченко Г.А. Эндокринология. Клинические рекомендации. – М.: ГЭОТАР-Медиа, 2007. – С. 47.  
Dedov II. (2016). Endocrinology. Clinical guidelines [*Endokrinologiya. Klinicheskie rekomendatsii*]. Moskva, 47.
4. Дедов И.И., Мельниченко Г.А., Мокрышева Н.Г., Рожинская Л.Я., Кузнецов Н.С., Пигарова Е.А., Еремкина А.К., Егшатын Л.В., Мамедова Е.О., Крупинова Ю.А. Первичный гиперпаратиреоз: клиника, диагностика, дифференциальная диагностика, методы лечения // Проблемы эндокринологии. – 2016. – Т. 62, № 6. – С. 40–77.  
Dedov II, Melnichenko GA, Mokrysheva NG, Rozhinskaya LYa, Kuznetsov NS, Pigarova EA, Eremkina AK, Egshatyan LV, Mamedova EO, Krupinova YuA. (2016). Primary hyperparathyroidism: the clinical picture, diagnostics, differential diagnostics, and methods of treatment [Pervichnyy giperparatireoz: klinika, diagnostika, differentsial'naya diagnostika, metody lecheniya]. *Problemy endokrinologii*, 62 (6), 40-77



5. Дедов И.И., Мельниченко Г.И., Фадеев В.В., Герасимов Г.А. Клинические рекомендации Российской ассоциации эндокринологов по диагностике и лечению узлового зоба // *Диагностика и лечение узлового зоба: Матер. 3-го Всерос. тиреологического конгр.* – М., 2004. – С. 512.

Dedov II, Melnichenko GI, Fadeev VV, Gerasimov GA. (2004). Clinical recommendations of the Russian Endocrinology Association for the diagnosis and treatment of nodular goiter [Klinicheskie rekomendatsii Rossiyskoy assotsiatsii endokrinologov po diagnostike i lecheniyu uzlovogo zoba]. *Diagnostika i lechenie uzlovogo zoba: Materialy 3-go Vserossiyskogo tireoidologicheskogo kongressa*, 5-12.

6. Ильичева Е.А., Булгатов Д.А., Жаркая А.В., Рой Т.А., Махутов В.Н., Боричевский В.И., Карасев В.П., Алдаранов Г.Ю., Овакимян Г.А., Корякина Л.Б., Рыжикова С.В. Опыт хирургического лечения вторичного гиперпаратиреоза с использованием интраоперационного мониторинга паратиреоидного гормона // *Таврический медико-биологический вестник*. – 2017. – Т. 20, № 3. – С. 46–51.

Ilyicheva EA, Bulgatov DA, Zharkaya AV, Roy TA, Makhutov VN, Borichevskiy VI, Karasev VP, Aldaranov GYu, Ovakimyan GA, Koryakina LB, Ryzhikova SV. (2017). Experience of surgical treatment of secondary hyperparathyroidism with intra-operational monitoring of parathyroid hormone [Opyt khirurgicheskogo lecheniya vtorichnogo giperparatireoza s ispol'zovaniem intraoperatsionnogo monitoringa paratireoidnogo gormona]. *Tavricheskiy mediko-biologicheskiiy vestnik*, 20 (3), 46-51.

7. Ильичёва Е.А., Жаркая А.В., Махутов В.Н., Рожанская Е.В., Булгатов Д.А., Папешина С.А. Опыт хирургического лечения вторичного гиперпаратиреоза // *Бюл. ВСНЦ СО РАМН*. – 2016. – Т. 1, № 4 (110). – С. 29–35.

Ilyicheva EA, Zharkaya AV, Makhutov VN, Rozhanskaya EV, Bulgatov DA, Papeshina SA. (2016). Experience of surgical treatment of secondary hyperparathyroidism [Opyt khirurgicheskogo lecheniya vtorichnogo giperparatireoza]. *Bulleten' Vostocno-Sibirskogo nauchnogo centra*, 4 (110), 29-35.

8. Ильичева Е.А., Махутов В.Н., Жаркая А.В., Иванова Т.В., Загородняя А.Н., Алдаранов Г.Ю., Булгатов Д.А., Карасев В.П., Боричевский В.И., Овакимян Г.А. Интраоперационный мониторинг интактного паратиреоидного гормона при хирургическом лечении первичного гиперпаратиреоза (анализ 118 наблюдений) // *Таврический медико-биологический вестник*. – 2017. – Т. 20, № 3. – С. 116–119.

Ilyicheva EA, Makhutov VN, Zharkaya AV, Ivanova TV, Zagorodnyaya AN, Aldaranov GYu, Bulgatov DA, Karasev VP, Borichevskiy VI, Ovakimyan GA. (2017). Intraoperative monitoring of intact parathyroid hormone in the surgical treatment of primary hyperparathyroidism (analysis of 118 cases) [Intraoperatsionnyiy monitoring intaktnogo paratireoidnogo gormona pri hirurgicheskome lechenii pervichnogo giperparatireoza (analiz 118 nablyudeniy)]. *Tavricheskiy mediko-biologicheskiiy vestnik*, 20 (3), 116-119.

9. Макаров И.В., Галкин Р.А., Шибанов В.Я., Сидоров А.Ю., Зайцев В.Е. Особенности клинического

течения и выбора тактики хирургического лечения диффузного токсического зоба у мужчин // *Современные аспекты хирургической эндокринологии: Матер. XXV Рос. симп. с участием терапевтов-эндокринологов («Калининские чтения»)*. – Самара: ООО «Офорт», 2015. – 504 с.

Makarov IV, Galkin RA, Shibanov VYa, Sidorov AYU, Zaytsev VE. (2015). Features of clinical course and choice of tactics for surgical treatment of diffuse toxic goiter in men [Osobennosti klinicheskogo techeniya i vybora taktiki khirurgicheskogo lecheniya diffuznogo toksicheskogo zoba u muzhchin]. *Materialy XXV Rossiyskogo simpoziuma s uchastiem terapevtov-endokrinologov («Kalininskie chteniya»)*. Samara, 504.

10. Федеральные клинические рекомендации по диагностике и лечению тиреотоксикоза с диффузным зобом (диффузный токсический зоб, болезнь Грейвса – Базедова), узловым/многочузловым зобом [Электронный ресурс]. – 2015. – Режим доступа: <https://minzdrav.gov-murman.ru/documents/poryadki-okazaniya-meditsinskoj-pomoshchi/tireo.pdf> (дата обращения 31.07.2017).

Federal clinical guidelines for the diagnosis and treatment of thyrotoxicosis with diffuse goiter (diffuse toxic goiter, Graves–Bazedov's disease), nodal / multinodular goiter. (2015). [Federal'nye klinicheskie rekomendatsii po diagnostike i lecheniyu tireotoksikoza s diffuznym zobom (diffuznyy toksicheskiiy zob, bolezni' Greivsa – Bazedova), uzlovym/mnogouzlovym zobom]. Available at: <https://minzdrav.gov-murman.ru/documents/poryadki-okazaniya-meditsinskoj-pomoshchi/tireo.pdf> (date of access 31.07.2017).

11. Харнас С.С., Мамаева С.К. Отдаленные результаты и качество жизни после хирургического лечения диффузного токсического зоба // *Эндокринная хирургия*. – 2008. – № 1. – С. 10–14.

Kharnas SS, Mamaeva SK. (2008). Long-term results and quality of life after surgical treatment of diffuse toxic goiter [Otdalennyye rezul'taty i kachestvo zhizni posle khirurgicheskogo lecheniya diffuznogo toksicheskogo zoba]. *Endokrinnyaya khirurgiya*, (1), 10-14

12. Хирургическая эндокринология: руководство / Под ред. А.П. Калинина, Н.А. Майстренко, П.С. Ветшева. – СПб.: Питер, 2004. – 960 с.

Kalinin AP, Maystrenko NA, Vetshev PS (eds.). (2004). Surgical endocrinology: guidelines [Khirurgicheskaya endokrinologiya: rukovodstvo]. Sankt-Peterburg, 960 p.


13. Cheng H, Soleas I, Ferko NC, Clymer JW, Amaral JF. (2015) A systematic review and meta-analysis of Harmonic Focus in thyroidectomy compared to conventional techniques. *Thyroid Res*, 8, 15. doi: 10.1186/s13044-015-0027-1.


14. He Q, Zhuang D, Zheng L, Fan Z, Zhou P, Zhu J, Duan S, Li Y, Ge Y, Lv Z, Cao L. (2014). Total parathyroidectomy with trace amounts of parathyroid tissue autotransplantation as the treatment of choice for secondary hyperparathyroidism: a single-center experience. *BMC Surg*, 5, 14-26. doi: 10.1186/1471-2482-14-26.


15. Kakava K, Tournis S, Papadakis G, Karelis I, Stampouloglou P, Kassi E, Triantafillopoulos I, Villiotou V, Karatzas T. (2016). Postsurgical hypoparathyroidism: A systematic review. *In Vivo*, 30 (3), 171-179.


16. Sakman G, Parsak CK, Balal M, Seydaoglu G, Eray IC, Sarıtaş G, Demircan O. (2014). Outcomes of total parathyroidectomy with autotransplantation versus sub-total parathyroidectomy with routine addition of thymectomy to both groups: single center experience of secondary hyperparathyroidism. *Balkan Med J*, 31 (1), 77-82

#### Information about the authors

**Ilyicheva Elena Alekseyevna** – Doctor of Medical Sciences, Professor, Head of the Scientific Department of Clinical Surgery, Irkutsk Scientific Centre of Surgery and Traumatology; Thoracic Surgeon at the Thoracic Surgical Department, Irkutsk Regional Clinical Hospital (664003, Irkutsk, ul. Bortsov Revolyutsii, 1; tel. (3952) 40-78-28; e-mail: lena\_isi@mail.ru)  ORCID orcid.org/0000-0002-2081-8665


**Zharkaya Anastasiya Valeryevna** – Candidate of Medical Sciences, Junior Research Officer at the Scientific Department of Clinical Surgery, Irkutsk Scientific Centre of Surgery and Traumatology; Surgeon at the Endocrinology Center, Irkutsk Regional Clinical Hospital (e-mail: ava\_irk@inbox.ru)  ORCID orcid.org/0000-0002-9337-2369


**Bulgatov Dmitriy Aleksandrovich** – Postgraduate at the Department of Advanced Level Surgery, Irkutsk State Medical University (664003, Irkutsk, ul. Krasnogo Vosstaniya, 1; e-mail: bbd-x@mail.ru)  ORCID orcid.org/0000-0002-2440-0813

**Makhutov Valeriy Nikolaevich** – Candidate of Medical Sciences, Head of the Thoracic Surgical Department, Irkutsk Regional Clinical Hospital (664079, Irkutsk, Yubileyniy, 100)  ORCID orcid.org/0000-0001-7318-7193

**Borichevskiy Vitaliy Ivanovich** – Thoracic Surgeon at the Thoracic Surgical Department, Irkutsk Regional Clinical Hospital  ORCID orcid.org/0000-0003-0203-0724

**Karasev Valeriy Petrovich** – Surgeon at the Thoracic Surgical Department, Irkutsk Regional Clinical Hospital  ORCID orcid.org/0000-0002-8513-3915

**Aldaranov Gennadiy Yuryevich** – Surgeon at the Thoracic Surgical Department, Irkutsk Regional Clinical Hospital  ORCID orcid.org/0000-0003-3123-1939

**Ovakimyan Gor Alesanovich** – Surgeon at the Thoracic Surgical Department, Irkutsk Regional Clinical Hospital  ORCID orcid.org/0000-0003-0657-3945